



**PATIENT**

Pixie Miron

**SPECIES**

Canine

**BREED**

Morkie

**SEX**

Female Spayed

**AGE**

6 years

**WEIGHT**

18.3lbs

**INTERPRETED BY**

Maggie Machen Lamy,  
 DVM DACVIM  
 (Cardiology)

**IMAGING PERFORMED BY**

Crystal Hill, RVT

**HOSPITAL NAME**

Dundas Animal  
 Hospital

**REFERRING VET**

Dr. Hall

**INVOICE**

46650

**DATE**

2/2/26

**PRESENTING CLINICAL SIGNS**

History: Presented for acute lethargy and anorexia, would not eat breakfast and didn't want to play. No history of coughing or exercise intolerance or low energy. New grade 3/6 heart murmur. HR: 168bpm; RR: 36bpm with harsh lung sounds bilaterally. Lip licking on PE, tense abdomen, BCS 7/9 treated with anti-nausea meds. CXR: suggestive of left-sided cardiomegaly with generalized lung. -Abnormal PE/Chem/CBC/UA Results: ALKP 1423, Chol 8.39; rest of BW WNL.

**ECHOCARDIOGRAM FINDINGS**

2D, m-mode, color flow and doppler imaging is available. The mitral valve is diffusely thickened with prolapse into the left atrial lumen. There is severe eccentric mitral regurgitation present. The MR velocity is normal. There is severe left atrial enlargement. There is mild left ventricular dilation. Left ventricular systolic function is hyperdynamic. Normal right heart. Mild thickening of the tricuspid valve with no TR. The aortic valve appears trileaflet with normal mobility. No significant AI. There is normal systolic flow velocity across the aortic valve. The main pulmonary artery is normal in diameter. The pulmonic valve is normal in appearance. Flow through the RVOT/PV is normal in velocity. Trace PI. No pericardial/pleural effusion or cardiac masses are seen.

**CARDIAC CHART**

CANINE CARDIAC PARAMETERS	MR VMAX (m/s)	TR VMAX (m/s)	LA/AO (Boon method)	LA/AO (Heart Base; Swe)	FS (%)	EF (%)	EPSS (cm)
NORMAL PARAMETER	4.5-5.5	<2.7	1.3	<1.6	28-40	40-100	<0.6
PATIENT	6.2		2.1	2.5	39	70	0.4
CANINE CARDIAC PARAMETERS	HR (BPM)	AV VMAX (m/s)	PV MAX (m/s)	BODY WEIGHT (kg)	LA 2D short axis Base view (cm)	LVIDd Avg; 2D and m-mode short axis (cm)	LVIDs Avg; 2D and m-mode short axis (cm)
NORMAL PARAMETER	50-100	0.7-1.7	0.7-1.6	BELOW	BELOW	BELOW	BELOW
PATIENT	180	1.7	1.2	8.3	2.8	3.4	2.1
*Normal chamber parameters expressed as a mean value (SD)				3	1.27 (5.3)	2.46 (2.46)	1.36 (5.5)
BODY WEIGHT DEPENDENT PARAMETERS				5	1.40 (4.5)	2.74 (5.2)	1.60 (4.7)
*Note: All measurements based upon multi-modal images and methods. An average value is reported.				10	1.50 (3.8)	3.27 (3.5)	2.06 (3.1)
				15	1.83 (2.0)	3.71 (2.4)	2.43 (2.1)
				20	2.02 (1.9)	4.14 (2.2)	2.80 (2.0)
Adapted from June Boon, Veterinary Echocardiography, 1998				25	2.18 (2.4)	4.48 (2.9)	3.10 (2.5)
Rishniw M and Hollis NE, J Vet Intern Med 2000; 14:429-435				30	2.33 (3.3)	4.83 (3.9)	3.39 (3.4)
Hansson et al, Vet Rad and Ultrasound 2002				35	2.48 (4.3)	5.17 (5.0)	3.69 (4.5)
Bonagura et al. Echocardiography: principles of interpretation, Vet Clin North Am 15:1177, 1995				40	2.62 (5.2)	5.48 (6.1)	3.96 (5.4)
				50	2.88 (7.1)	6.07 (8.3)	4.46 (7.4)

**INTERPRETATION OF THE FINDINGS & FURTHER RECOMMENDATIONS**

Chronic degenerative valve disease causing severe mitral regurgitation. The LA is significantly dilated, indicating a high risk for clinical signs going forward. No additional concurrent issues such as systolic dysfunction are documented.

With this degree of left heart changes, the risk for spontaneous congestive heart failure is elevated and cardiac supportive medications are indicated as below. A weak diuretic (spironolactone) is included given high risk for decompensation in the future even with no reported symptoms for potential survival benefit. Assessment of progression in the future will help predict long term outcome; however, prognosis is guarded at this stage (late B2).



**PATIENT**

Pixie Miron

Unfortunately, there is increased risk for CHF, development of arrhythmias/LA tear, syncope and/or sudden death in the future.

**SPECIES**

Canine

Close monitoring for development of associated clinical signs (development of a cough, labored breathing, exercise intolerance or worsening collapse episodes) is recommended. **Monitoring of sleeping breathing rates is recommended as the best way to screen for CHF at home.**

**BREED**

Morkie

**Elective anesthesia is not advised with severe disease**, as there is high risk for complication. Risk versus benefit must be considered. If necessary, cardiac protective drug choices (opioid/benzodiazepine premedication, propofol or alfaxalone induction, iso or sevoflurane gas) are recommended. Pre-oxygenate for 5-10 minutes prior to induction and recover in O2 cage. Monitor for arrhythmias, hypotension, and hypoxia both intra and post-operatively and intervene as necessary. Moderate IV fluid restriction is recommended to avoid fluid overload. Avoid heart rate stimulating drugs such as atropine unless clinically indicated. Avoid alpha 2 agonists.

**SEX**

Female Spayed

**AGE**

6 years

Omega fatty acid supplementation and mild salt restriction may also be of some long-term benefit.

**WEIGHT**

18.3lbs

**PLAN**

A screening BP is recommended. Administer Pimobendan 0.3mg/kg PO q12h. Institute ACE-I (benazepril or enalapril) 0.5mg/kg PO q12h. Institute spironolactone 1-2mg/kg PO q12h.

**INTERPRETED BY**

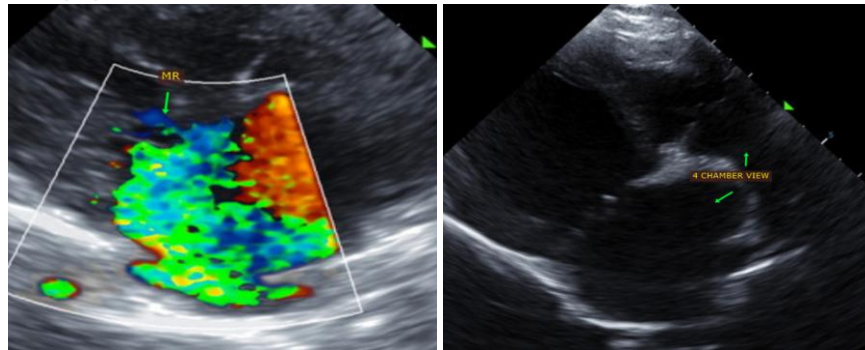
Maggie Machen Lamy,  
 DVM DACVIM  
 (Cardiology)

Monitor renal values/BP 1-2 weeks, then every 3-4 months lifelong to ensure tolerance of medications.

A recheck echocardiogram is recommended in 6 months to screen for progression, sooner if clinical signs arise in the interim.

**IMAGING PERFORMED BY**

Crystal Hill, RVT



**HOSPITAL NAME**

Dundas Animal Hospital

**REFERRING VET**

Dr. Hall

**INVOICE**

46650

The information and recommendations provided are based on the images presented by the referring veterinarian. No evaluation can be communicated regarding pathology that was not visible in the image/video clips provided.

**DATE**

2/2/26

Thank you for this referral. This report was generated using transcription software, and minor dictation errors may be present. If the clinical or image interpretation does not parallel your findings or if I can be of any further assistance, please contact me.

**Maggie Machen Lamy, DVM**  
 Diplomate of the American College of Veterinary Internal Medicine (Cardiology)  
 info@sonopath.com